

Nipple-Sparing Mastectomy

Scott L. Spear, M.D.
Catherine M. Hannan, M.D.
Shawna C. Willey, M.D.
Costanza Cocilovo, M.D.

Washington, D.C.

Background: The debate over nipple-sparing mastectomy continues to evolve. Over the past several years, it has become more widely accepted, especially in the setting of prophylactic mastectomy, but its role in the treatment of breast cancer has only recently been reexamined.

Methods: Two indications for the procedure are discussed: prophylactic, for the high-risk patient; and the more controversial topic, therapeutic nipple-sparing mastectomy, for the patient with breast cancer. A review of the literature suggests that certain breast cancers may be amenable to retaining the nipple if they meet specific oncologic criteria: tumor size 3 cm or less, at least 2 cm from the nipple, not multicentric, and with clinically negative nodes. Moreover, newer technologies such as magnetic resonance imaging and preoperative mammotome biopsy may make the procedure even safer in this setting. Practical and technical aspects of the procedure are discussed, including patient selection.

Results: The accumulating data from multiple series of nipple-sparing mastectomy show that properly screened patients have a low risk of local cancer recurrence, that recurrences occur rarely in the nipple, and that recurrences in the nipple can be managed by removing the nipple.

Conclusions: Despite continued controversy and the need for more long-term outcome data, nipple-sparing mastectomy is a procedure that is gaining increasing visibility and acceptance. Provided that certain oncologic and practical criteria are applied, it has the potential for allowing less invasive surgery and improved cosmetic outcomes without increased oncologic risk in appropriately selected patients. (*Plast. Reconstr. Surg.* 123: 1665, 2009.)

It should not come as a surprise that “nipple-sparing” mastectomy would surface as the next frontier in the search for ever-improving methods in managing breast cancer. Looking back over the past several decades, it was not so long ago that radical mastectomy was the recommended treatment for breast cancer, and physicians were reluctant to challenge that standard dogma of the day. Since that time, we have seen a steady evolution of more targeted techniques with equal or better effectiveness in terms of cancer treatment and reducing the extent of surgery and surgical risk.

One of the frequently postulated reasons for a high mortality rate from breast cancer was the fear of mutilation and disfigurement that would necessarily come with surgery. Thus, in the case of breast cancer, the fear of death and of the disease is compounded by the fear of disfigurement from

treating the disease. Over the past 40 years, radical mastectomy has been replaced by a progression of more modulated treatments, including modified radical mastectomy, breast conservation therapy, sentinel node sampling, skin-sparing mastectomy, brachytherapy, and now possibly nipple-sparing mastectomy.

Although the medical profession is rightly comforted by the progress that has been made in treating breast cancer with the simultaneous improvement in survival with less surgery, the fact remains that our interventions carry with them substantial hardships for the patient. This is true for the surgery and perhaps even more so for the chemotherapy, hormonal therapy, and radiation therapy that these women endure. A frequent comment from the patients whom we encounter was that the surgery was the easiest part.

The challenge for thoughtful medical professionals is to continue to search for increasingly or

From the Department of Plastic Surgery, Georgetown University Hospital, and the Departments of Plastic Surgery and Surgery, Georgetown University.

Received for publication March 25, 2008; accepted September 19, 2008.

Copyright ©2009 by the American Society of Plastic Surgeons

DOI: 10.1097/PRS.0b013e3181a64d94

Disclosures: Scott L. Spear, M.D., is a paid consultant to Allergan, LifeCell, and Ethicon. None of the other authors has any financial conflicts of interest.

equally effective treatments with less collateral damage or morbidity. In the case of nipple-sparing mastectomy, the challenge is to refine criteria for patient selection, establish best surgical techniques, and coordinate options for reconstruction.

A careful look at nipple-sparing mastectomy might also impact patient decision making regarding choosing between breast conservative therapy and mastectomy. With breast conservative therapy, the nipple, the skin of the breast, the breast parenchyma, and nipple sensation can usually be partly preserved. Of those four, no doubt the least important to the woman is the parenchyma itself. Thus, with nipple-sparing mastectomy, there is the possibility that a form of breast conservation can also be achieved, with the difference being replacement of the parenchyma and likely loss of sensation. Much has been written regarding the symbolic and psychological importance of the nipple to the woman, and its loss may be as or more psychologically significant than the loss of the

breast mound itself. In addition, even though surgeons have developed techniques to create a nipple and areola, the results of those techniques are inconsistent and rarely achieve as natural an appearance as the native nipple; and even in the case of the very finest examples of nipple reconstruction, it is unlikely that the reconstructed nipple provides the same psychological benefit as the original.

From a technical point of view, there are several potential advantages of a nipple-sparing mastectomy. The most obvious of course is preserving the nipple itself for its physical properties of shape, volume, projection, color, and texture (Fig. 1). However, there are other benefits. The unique and irreplaceable features of each woman's nipple are matched by the unique color, texture, and volume of the areola. The nipple and areola combined represent a certain significant amount of valuable skin located in a prime location on the most projecting portion of the breast (Fig. 2). The

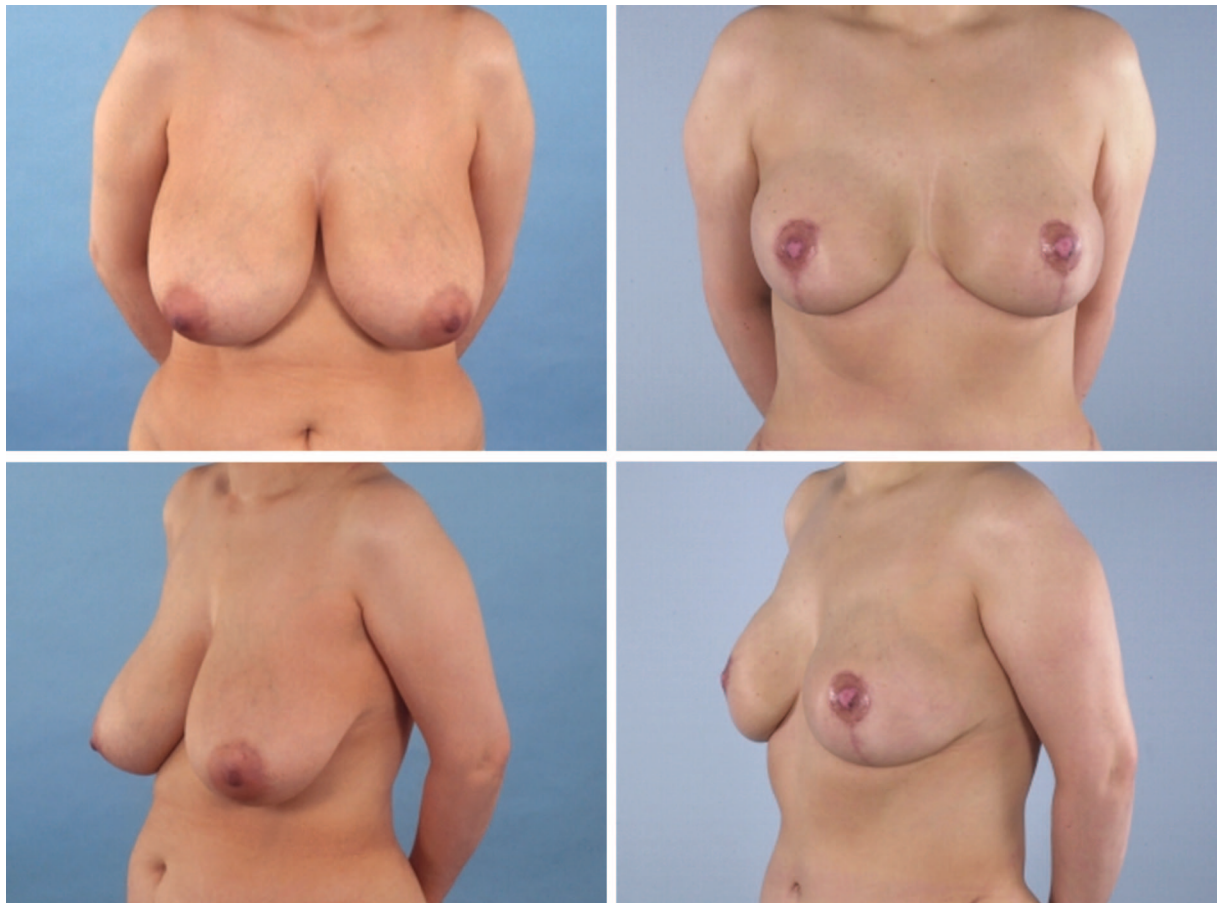


Fig. 1. Patient 4, a 53-year-old woman with a family history of breast cancer, elected to undergo bilateral prophylactic mastectomy. Preoperative views (*left*) show significant ptosis. (*Right*) Appearance of the patient 6 months after bilateral single-pedicle transverse rectus abdominis myocutaneous flap with free nipple graft reconstruction.

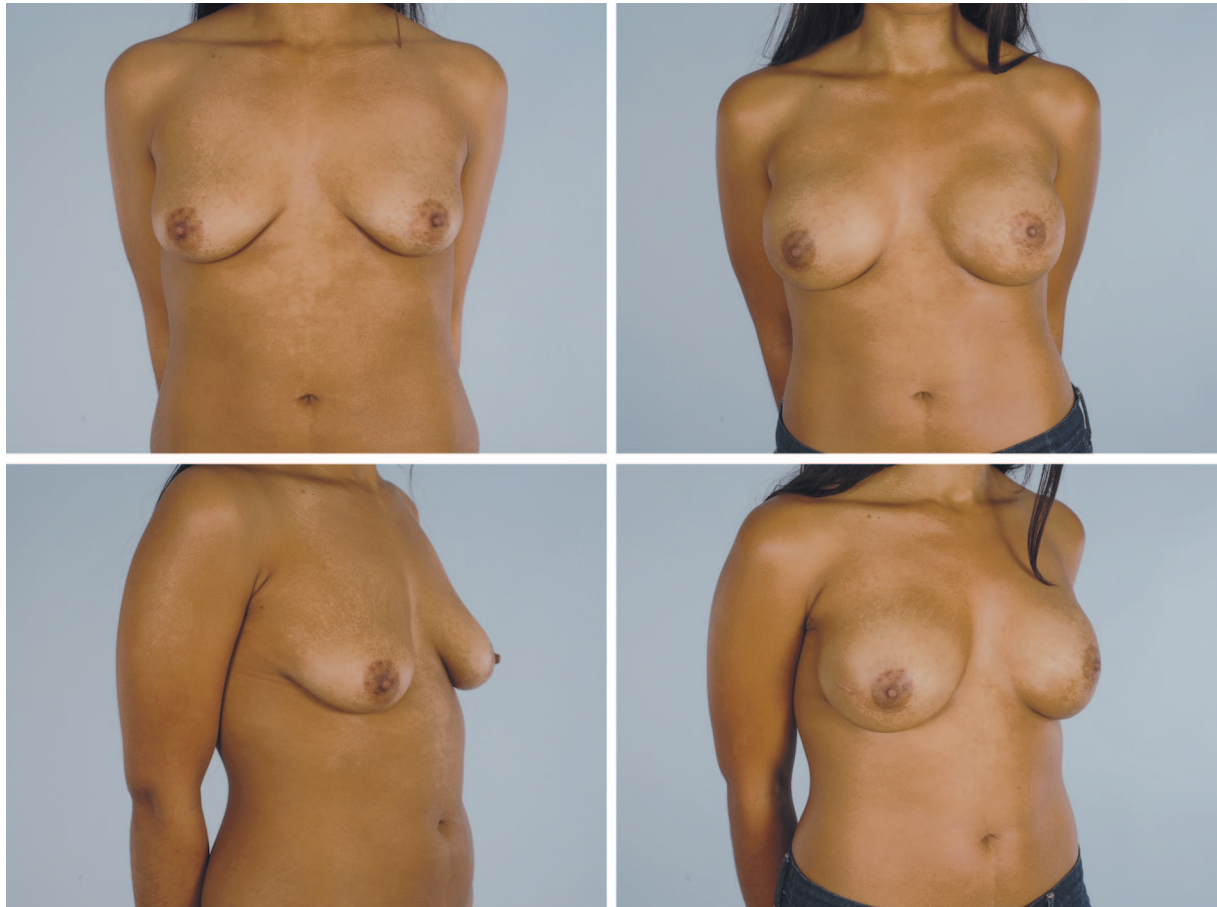


Fig. 2. Patient 1, a 26-year-old woman with a strong family history of breast cancer who is *BRCA* gene positive, elected to undergo bilateral nipple-sparing mastectomies with immediate reconstruction with AlloDerm (LifeCell Corp., Branchburg, N.J.) and Natrelle style 133 MV tissue expanders (Allergan, Inc., Irvine, Calif.) filled to volumes of 400 cc. (Left) Preoperative views and (right) appearance 6 months postoperatively, after exchange of expanders to Natrelle smooth round silicone-filled implants, style 15, with a volume of 492 cc, placed bilaterally.

larger the nipple and areola, the greater the loss. Preserving the nipple or even just the areola also allows the possibility that a scar will not need to traverse the front of the breast, thus replacing the traditional scar associated with a mastectomy with a scar instead previously associated with a biopsy or lumpectomy. The purpose of this article is to review the scientific information available for nipple-sparing mastectomy in two clinical scenarios: prophylactic mastectomy (risk-reduction mastectomy) and therapeutic mastectomy.

RISK-REDUCTION MASTECTOMY

The concept of nipple-sparing mastectomy was first popularized in the 1960s and 1970s as subcutaneous mastectomy.¹ That procedure for risk reduction quickly fell out of favor for a number of good reasons. Most significantly, there were no scientifically based selection criteria and there-

fore no possibility of ever demonstrating efficacy. Beyond that, the reconstructive techniques of the day were relatively crude, the results were inconsistent, the best outcomes were not impressive, the complication rate was high, and a significant amount of breast tissue was intentionally left behind.

All this changed with the seminal report by Hartmann et al.² published in the *New England Journal of Medicine* in 1999. Over the preceding 20 years or longer, the Mayo Clinic in Rochester, Minnesota, had been a center of sorts for prophylactic mastectomy where the techniques were largely of the historic subcutaneous mastectomy type, but where the medical records were excellent and data could be extracted and reassessed using computer models and other more modern techniques. The data from that series of 639 women of moderate and high risk for development of breast cancer demonstrated that prophylactic mastectomy did in-

deed have a protective benefit, reducing the risk of breast cancer in both high-risk and moderate-risk groups by 81 to 94 percent. In their later study in 2001 based on the same patient series, a similar risk reduction was found in patients with the *BRCA1* or *BRCA2* gene mutation.³ Ninety percent of the mastectomies in that series were nipple-sparing of the subcutaneous variety. There was no statistically significant difference in the cancer-preventing benefit whether the nipple was removed or retained.

In the context of risk reduction, other series report similar experience. McDonnell et al.,⁴ also from the Mayo Clinic, in 2001 reported 745 women with a first breast cancer and a strong family history of breast cancer that underwent contralateral prophylactic mastectomy, with a 94 to 96 percent risk reduction. All told, there were eight breast cancers versus 156 predicted. Forty-one percent of the mastectomies spared the nipple and 59 percent did not. The eight cancers that developed were split evenly between the nipple-sparing and nipple removal groups. None of the eight cancers developed near the nipple.

In 2004, Crowe⁵ reported on 17 nipple-sparing prophylactic mastectomies. They recommend a lateral incision for improved nipple-areola survivability. There were no occult cancers seen on frozen or permanent examination beneath the nipple, and no cancers have developed since.

In 2006, Sachini⁶ published a larger multicenter experience that included the Memorial Sloan-Kettering Cancer Center in New York. Altogether, there were 55 patients who underwent nipple-sparing prophylactic mastectomies. There were no recurrent or new cancers in the nipple, with a mean follow-up of 24 months. Two cancers did develop in the periphery of the breast, one in the axillary tail at 24 months and one in the upper outer quadrant at 62 months. The majority of their procedures were performed through a periareolar incision that included coring out the nipple. Twenty-two of 192 nipples (11 percent) suffered some degree of necrosis.

Rebeck et al.⁷ published the experience from the multicenter Prose Study Group of 483 *BRCA1*- and *BRCA2*-positive women including 105 who underwent bilateral prophylactic mastectomy including 29 nipple-sparing mastectomies. Two of those 105 developed breast cancer, in contrast to 184 cancers among 378 patients in the control group, yielding a 90 percent or more risk reduction. The two cancers that developed included one in the axilla and one in the breast. There was no statistically significant difference in the occurrence of

cancer between the nipple-sparing and non-nipple-sparing groups.

NIPPLE-SPARING MASTECTOMY IN THE TREATMENT OF BREAST CANCER

If surgeons have been reluctant to embrace nipple-sparing in the context of risk reduction, they have been even more reluctant to do so in the face of established breast cancer. Nevertheless, the gradual acceptance of skin-sparing mastectomy has encouraged some to look more critically at the concept of nipple-sparing mastectomy as a treatment for breast cancer.

There were many inconsistent reports from the 1970s and 1980s regarding the likelihood of nipple involvement with cancer in the face of known ipsilateral breast cancer. Reports of nipple involvement with cancer varied widely from 0 to 58 percent. Those data come from an era of later diagnosis and more advanced disease. Furthermore, the methodology for tissue examination of those studies and the criteria for describing “involvement” were not uniform.

With the increased interest in nipple-sparing mastectomy, more relevant studies have recently been performed. Laronga et al.⁸ from the M. D. Anderson Cancer Center reported in 1999 on 326 patients whose breasts were examined after skin-sparing mastectomy. They found 16 instances (5.6 percent) of occult tumor involvement. They believe four of these would have been identified on frozen section if it had been performed. The only statistically significant predictors of nipple involvement were location (subareolar or multicentric) and axillary nodal status. The authors speculate that their finding of a relatively low incidence of occult nipple-sparing mastectomy involvement might reflect their selective criteria for nipple-sparing mastectomy in the first place. They conclude that it would be appropriate to offer nipple-sparing mastectomy preservation in clinically axillary node-negative patients with tumors located on the periphery of the breast. They estimate that in that group, the probability of missing occult tumor in the nipple-sparing mastectomy would be less than 2 percent.

Gerber and Krause⁹ from Rostock, Germany, reported in 2003 their experience with skin-sparing mastectomy including the nipple-areola complex. At 59 months, there were six recurrences (5.4 percent) in 112 nipple-sparing mastectomies—two on the chest wall, two in the upper breast, one in the fold, and one that was noninvasive in the nipple. There were 11 recurrences (8.2 percent) among 134 women who had the nipple removed. They found

that nipple-areola complex tumor involvement depended predominately on the distance of the tumor from the nipple-areola complex. They believe that their data justify preservation of the nipple-areola complex in patients with tumors at least 2 cm from the nipple, no extensive intraductal component (extensive defined as >25 percent), and clear margins.

Crowe⁵ at the Cleveland Clinic attempted nipple-sparing mastectomy in 54 women with intraoperative frozen section findings of cancer in the nipple, and aborted the procedure in six patients. Of the 48 women who underwent nipple-sparing mastectomy, three (6.2 percent) had partial nipple loss. Candidates for nipple-sparing mastectomy were excluded if the tumor was 3.5 cm in diameter or greater, if the tumor was central, if the patient had undergone neoadjuvant chemotherapy, and

if there was inflammatory breast cancer or Paget disease. They recommended lateral incisions whenever possible.

In Sacchini's⁶ report of nipple-sparing mastectomy in 68 patients with breast cancer, they excluded women with very large breasts, very ptotic breasts, and tumors within 1 cm of the areola. Fourteen patients of the original 82 were excluded and not included among the remaining 68 because of tumor involvement found on permanent pathologic evaluations. They did not use frozen section in their series.

More recently, Laura Esserman and colleagues from San Francisco described their experience with nipple-sparing mastectomy in 64 breasts in 43 women.¹⁰ Twenty-nine breasts were prophylactic and 24 were for invasive or ductal carcinoma in situ. They recommended high-resolution mag-

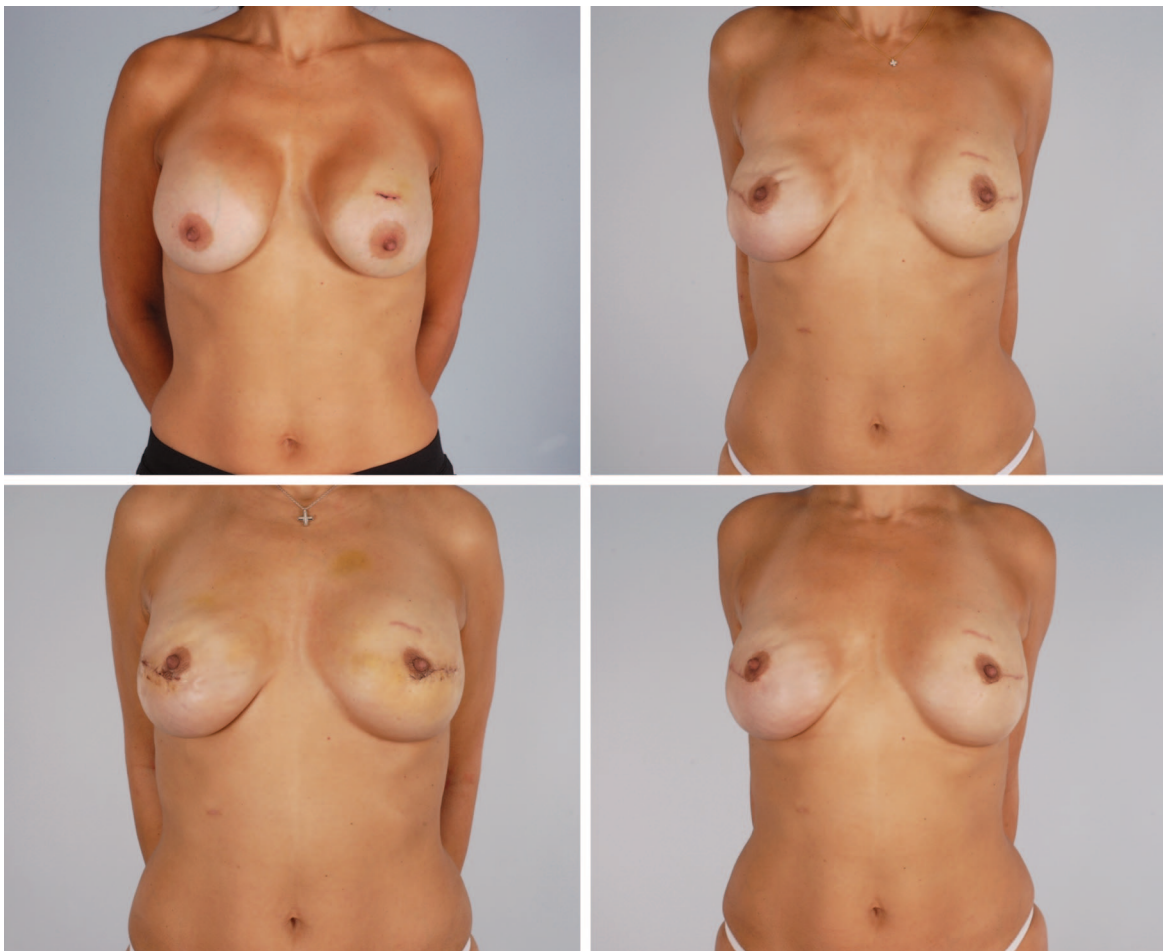


Fig. 3. Patient 3, a 42-year-old woman with abnormal mammogram of the left breast leading to multiple excisional biopsies for ductal carcinoma in situ, ultimately underwent bilateral nipple-sparing mastectomies with negative intraoperative frozen sections. (Above, left) Preoperative view. (Above, right) Appearance 2 months postoperatively after immediate reconstruction with AlloDerm and Natrelle style 15 smooth round silicone implants with volumes of 371 cc. (Below, left) Appearance 4 months postoperatively. (Below, right) Result at 5 months postoperatively.

netic resonance imaging with fat suppression to exclude tumor within 2 cm of the nipple. Nevertheless, even with magnetic resonance imaging screening, two occult cancers were found on frozen section. Furthermore, they recommended against nipple-sparing mastectomy in cases with large, centrally located tumors, skin involvement by tumor, or magnetic resonance imaging evidence of tumor within 2 cm of the nipple.

Of similar interest is the recommendation by Govindarajulu et al.¹¹ from Bristol, England, to screen patients for possible nipple-sparing mastectomy by performing preoperative ultrasound-guided mammotome assessment. Thirty-three women had 36 procedures, and seven of the 36 had a positive biopsy specimen. The histopathology of the mastectomy specimen correlated 100 percent with the mammotome biopsy specimen.

DISCUSSION

It is clear from a review of the literature of the past 15 years that the subject of nipple-sparing mastectomy is complex and evolving. The subject is properly divided into two parts: risk prevention and therapeutic mastectomy. There now seems little doubt that nipple-sparing mastectomy is an oncologically safe approach to prophylactic mastectomy. For that purpose, proper patient selection and technique remain open questions. In the case of prophylactic mastectomy, it is therefore not whether nipple-sparing mastectomy is oncologically safe, but how to do it and for which patients. The larger or more ptotic the breast, the more complex the planning. Strategies for saving the nipple in these more challenging cases could include reducing the skin envelope before the mastectomy, grafting the nip-

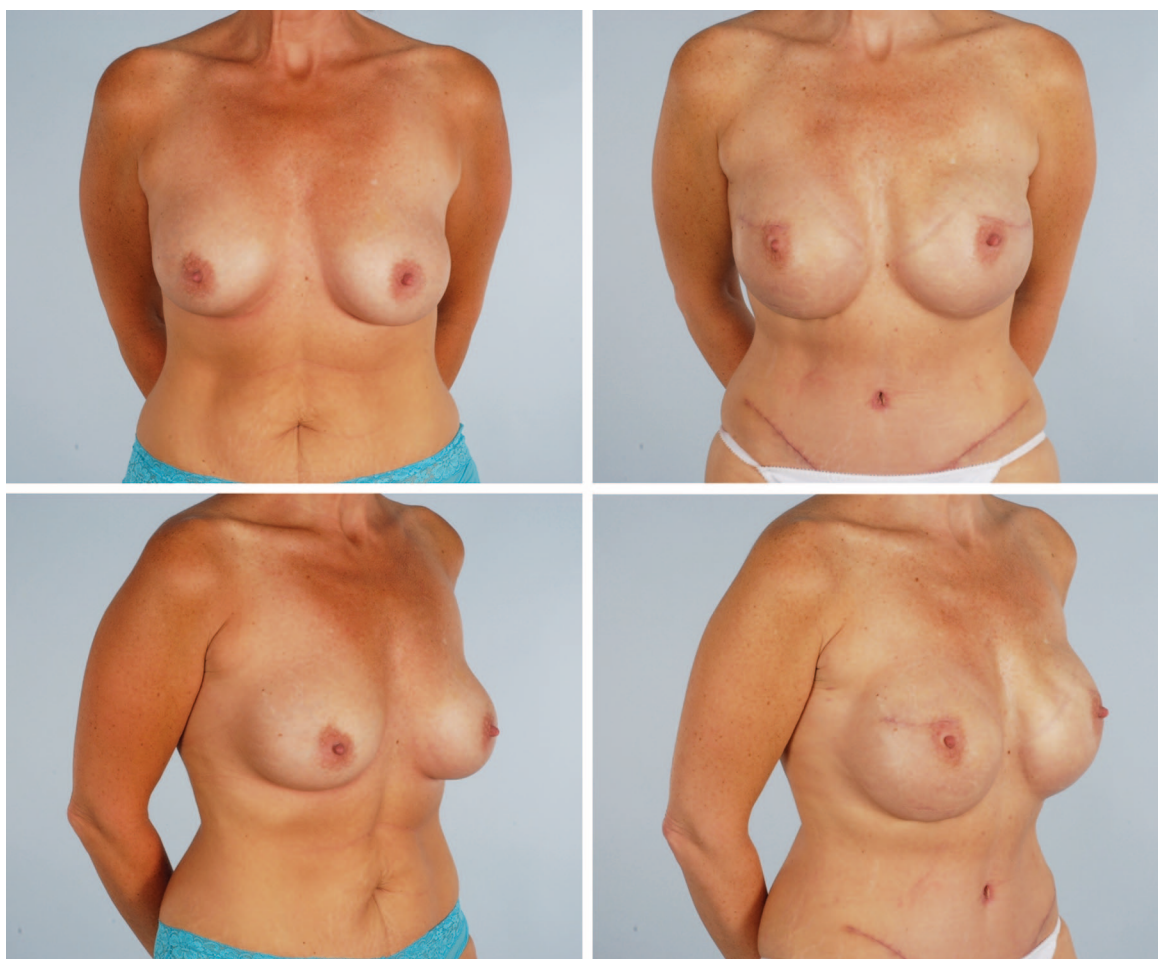

Fig. 4. Patient 2, a 42-year-old woman with ductal carcinoma in situ of the left breast, elected to have bilateral nipple-sparing mastectomies with immediate reconstruction using AlloDerm and Natrelle 133 MV 500-cc tissue expander filled to 350 cc bilaterally. (Left) Preoperatively views. (Right) Appearance 4 months after tissue expander exchange to bilateral Natrelle style 15 600-cc smooth silicone implants.

ple-areola complex, or performing a mastopexy at the same time as the mastectomy.

Nipple-sparing mastectomy at the time of therapeutic mastectomy remains more controversial (Figs. 3 and 4). There is developing consensus by those interested in nipple-sparing mastectomy as a possibility with therapeutic mastectomy that it is best suited for women who meet certain criteria. On clinical assessment, they ideally should have tumors 3 cm in diameter or less, 2 cm away from center of the nipple, clinically negative axillae or sentinel node negative, no skin involvement, and no inflammatory breast cancer. If possible, they should undergo preoperative magnetic resonance imaging of the breast to further exclude nipple involvement. In any case, the final decision to spare the nipple must ultimately await frozen and then definitive pathologic section. Assuming that all the oncologic criteria are met in the patient with breast cancer, the issues come back to patient selection and technique. In that regard, the answers are the same or similar as with prophylactic mastectomy. The collective data suggest that, using the above criteria, the risk of occult tumor in the nipple should be 5 to 15 percent; that frozen section of the base of the nipple will identify many if not most of those occult tumors; and that the risk of occult tumor still being present in patients screened as above with frozen section–negative findings is as low as 4 percent (Fig. 5).¹²

The ability to diagnose breast cancer at an earlier stage and to stage it more accurately using the above criteria enhanced with magnetic resonance imaging, improved mammography, and possibly even preoperative subareolar mammo-tome biopsy, should allow surgeons to offer nipple-sparing mastectomy to the properly screened patient with a high level of confidence of not finding occult disease. If occult disease is encountered on pathologic examination, the nipple and perhaps the areola should be removed at the time of the mastectomy or at a later date.

Although selection criteria can be used to identify patients at lower risk for occult tumor in the nipple, it should not be inferred that other patients cannot be considered if they so desire. It does mean that they are higher risk for having occult cancer in the nipple, resulting in removal of the nipple at the time of mastectomy or shortly thereafter.

Nipple-sparing mastectomy is not meant just to be the solution for the patient who is a poor candidate for breast conservation, because many of those patients would also be poor candidates for nipple-sparing mastectomy. Rather, it is also meant to be another option for the patient who might want

to retain all the surface landmarks of the breast but forego radiation therapy.

In addition to the important oncologic issues, selection criteria must also include the anatomy of the breast itself. In most cases, nipple-sparing mastectomy equates with removing little if any skin. For that reason, the larger or more ptotic the breast, the more likely there will be nipple or flap necrosis, or both. In cases where the skin flaps would be too long, the nipple-areola complex could be harvested and grafted onto a flap, preferably a latissimus or transverse rectus abdominis myocutaneous flap. Such flap and nipple-areola complex graft combinations are highly complex efforts best practiced by very experienced teams.

Regarding technique, recent reports suggest that the best incisions are either lateral, radial, lateral mammary fold, inframammary fold, or in any case do not traverse more than one-third of the areola diameter. The inframammary fold incision is not recommended, except for very small breasts, because of several concerns including safe access to the upper portion of the breast,⁵ assessment of subareolar tissue, access to the axilla, flap necrosis, and possible need for removing the nipple.

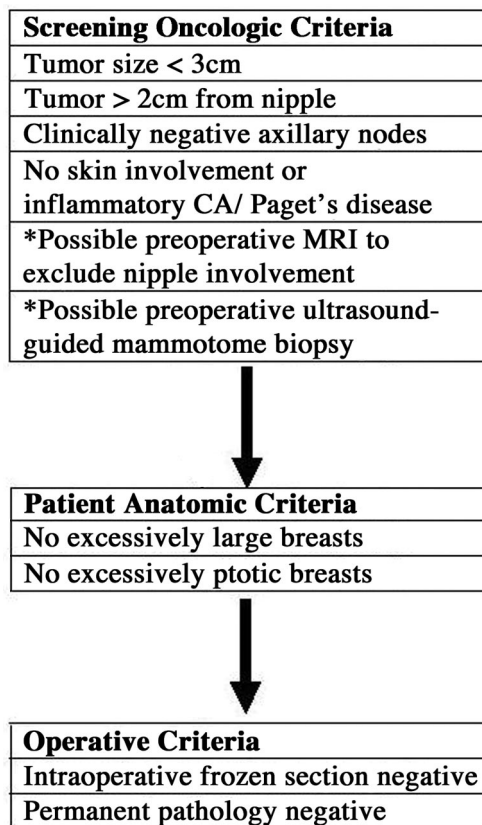


Fig. 5. Georgetown algorithm for therapeutic nipple-sparing mastectomy.

Table 1. Selection Criteria for Nipple-Sparing Mastectomy in the Treatment of Breast Cancer by Various Authors

Authors	Tumor Size (cm)	Distance from Nipple (cm)	Tumor Characteristics	Other
Laronga et al., 1999 ^{8*}	<2 cm	Periphery	Well differentiated	Negative node status
Gerber and Krause, 2003 ⁹		>2 cm		<25% intraductal component, negative frozen section
Crowe, 2004 ⁵		>1 cm		Very ptotic or large breasts excluded
Sacchini, 2006 ⁶	<3.5 cm	Noncentral	No inflammatory CA or Paget disease	No neoadjuvant chemotherapy
Wijayanayagam et al., 2008 ¹⁰	No "large" tumors	>2 cm	No skin involvement	Preoperative MRI of nipple to evaluate tumor

CA, carcinoma; MRI, magnetic resonance imaging.

*Based on pathologic examination of skin-sparing mastectomy specimens predicting risk of nipple involvement. Statistically significant predictors were location (subareolar or multicentric) and positive axillary nodes.

There are disadvantages to sparing the nipple. First, the incision may be considerably smaller. Furthermore, with longer mastectomy flaps, there is a greater risk of mastectomy flap necrosis and, ultimately, nipple necrosis. There is the possibility of having to return to the operating room to reexcise positive margins and even remove the nipple and/or areola.

The greatest advantage of nipple-sparing mastectomy is its utility with prosthetic reconstruction. However, in the case of periareolar skin-sparing mastectomy where a flap reconstruction is planned, the nipple can often be preserved as a graft on the autologous reconstruction.

Once a patient has met oncologic criteria for possible preservation of the nipple-areola complex (Table 1) or elects to undergo prophylactic mastectomy, the patient must be evaluated from a reconstructive standpoint. As stated previously, very large or very ptotic breasts may not be good candidates for simple nipple-sparing mastectomy, or may require a first-stage reduction or mastopexy before the second-stage mastectomy. Most often, the periareolar incision with lateral extension is the best incision, as this allows the best access to the entire breast. Intraoperatively, in the case of a therapeutic mastectomy, a biopsy of the retroareolar tissue can easily be sent for frozen section. If this is positive, the nipple and/or areola is removed immediately. If negative, the operation proceeds as planned. If the final pathologic evaluation demonstrates cancer involvement, the nipple and possibly areola are removed later. This reexcision, essentially a skin-only procedure, should not cause any interference with the preceding reconstruction. A major benefit of the periareolar incision in these cases is the simplicity of returning to remove the nipple using the same surgical incision rather than having to make a separate incision on the breast.

The accumulating data from multiple series of nipple-sparing mastectomy show that properly screened patients have a low risk of local cancer recurrence, that recurrences occur rarely in the nipple, and that recurrences in the nipple can be managed by removing the nipple.⁹ In an article published recently in this *Journal*,¹³ we reported a series of 101 breasts (74 patients) after prophylactic mastectomy, including 28 breasts (16 patients) undergoing nipple-sparing mastectomy from 2000 to 2005. There were no subsequent breast cancers.

The goal of nipple-sparing mastectomy is to produce outstanding cosmetic results with little or no sacrifice of oncologic or surgical safety. For this concept to be worthwhile to the patient, there must be agreement that the goal of improved cosmesis is worth the additional preoperative and intraoperative screening, evaluation, testing, and possible increased oncologic risk even if it is believed to be small.

Scott L. Spear, M.D.

Department of Plastic Surgery
Georgetown University Hospital
3800 Reservoir Road, NW 1PHC
Washington, D.C. 20007
spears@gunet.georgetown.edu

REFERENCES

- Freeman BS. Subcutaneous mastectomy. *Plast Reconstr Surg*. 1962;30:676–682.
- Hartmann LC, Schaid DJ, Woods JE, et al. Efficacy of bilateral prophylactic mastectomy in women with a family history of breast cancer. *N Engl J Med*. 1999;340:77–84.
- Hartmann LC, Sellers TA, Schaid DJ, et al. Efficacy of bilateral prophylactic mastectomy in BRCA1 and BRCA2 gene mutation carriers. *J Natl Cancer Inst*. 2001;93:1633–1637.
- McDonnell SK, Schaid DJ, Myers JL, et al. Efficacy of contralateral prophylactic mastectomy in women with a personal and family history of breast cancer. *J Clin Oncol*. 2001;19:3938–3943.

5. Crowe JP. Nipple-sparing mastectomy: Technique and results of 54 procedures. *Arch Surg*. 2004;139:148–150.
6. Sacchini V. Nipple-sparing mastectomy for breast cancer and risk reduction: Oncologic or technical problem? *J Am Coll Surg*. 2006;203:704–714.
7. Rebbeck TR, Friebel T, Lynch HT, et al. Bilateral prophylactic mastectomy reduces breast cancer risk in BRCA1 and BRCA2 mutation carriers: The Prose Study Group. *J Clin Oncol*. 2004;22:1055–1062.
8. Laronga C, Kemp B, Johnston D, Robb GL, Singletary SE. The incidence of occult nipple-areola complex involvement in breast cancer patients receiving a skin-sparing mastectomy. *Ann Surg Oncol*. 1999;6:609–613.
9. Gerber B, Krause A. Skin-sparing mastectomy with conservation on the nipple-areola complex and autologous reconstruction is an oncologically safe procedure. *Ann Surg*. 2003;238:120–127.
10. Wijayanayagam A, Kumar AS, Foster RD, Esserman LJ. Optimizing the total skin-sparing mastectomy. *Arch Surg*. 2008;143:38–45.
11. Govindarajulu S, Narreddy S, Shere MH, Ibrahim NB, Sahu AK, Cawthorn SJ. Preoperative mammotome biopsy of ducts beneath the nipple areola complex. *Eur J Surg Oncol*. 2006;32:410–412.
12. Vljacic Z, Zic R, Stanec S, Lambasa S, Petroveci M, Stanec Z. Nipple-areola complex preservation predictive factors of neoplastic nipple-areola complex invasion. *Ann Plast Surg*. 2005;55:240–244.
13. Spear S, Schwarz KA, Venturi ML, Barbosa T, Al-Attar A. Prophylactic mastectomy and reconstruction: Clinical outcomes and patient satisfaction. *Plast Reconstr Surg*. 2008;122:1–9.

Instructions for Authors: *Update*

Registering Clinical Trials

Beginning in July of 2007, *PRS* has required all articles reporting results of clinical trials to be registered in a public trials registry that is in conformity with the International Committee of Medical Journal Editors (ICMJE). All clinical trials, regardless of when they were completed, and secondary analyses of original clinical trials must be registered before submission of a manuscript based on the trial. Phase I trials designed to study pharmacokinetics or major toxicity are exempt.

Manuscripts reporting on clinical trials (as defined above) should indicate that the trial is registered and include the registry information on a separate page, immediately following the authors' financial disclosure information. Required registry information includes trial registry name, registration identification number, and the URL for the registry.

Trials should be registered in one of the following trial registries:

- <http://www.clinicaltrials.gov/> (Clinical Trials)
- <http://actr.org.au> (Australian Clinical Trials Registry)
- <http://isrctn.org> (ISRCTN Register)
- <http://www.trialregister.nl/trialreg/index.asp> (Netherlands Trial Register)
- <http://www.umin.ac.jp/ctr> (UMIN Clinical Trials Registry)

More information on registering clinical trials can be found in the following article: Rohrich, R. J., and Longaker, M. T. Registering clinical trials in *Plastic and Reconstructive Surgery*. *Plast. Reconstr. Surg*. 119: 1097, 2007.