

# Fat Injection to Correct Contour Deformities in the Reconstructed Breast

Scott L. Spear, M.D., Henry B. Wilson, M.D., and Michelle D. Lockwood, M.D.

Washington, D.C.

**Background:** A ten-year, single-surgeon study of 37 patients from 1993 to 2003 who underwent fat injections to improve contour deformities in their reconstructed breasts was reviewed.

**Methods:** Fat was harvested from elsewhere in the body using a low-pressure syringe lipoaspiration system, washed gently with saline, and injected into depressions along the margins of reconstructed breasts. Blinded physician observers judged preoperative and postoperative photographs of breasts injected with fat and categorized the degree of contour improvement as substantial, minimal to moderate, or none. Complications of fat injections were noted. A total of 43 breasts in 37 patients were injected with autologous fat during 47 discrete events; some patients had the procedure repeated and some were treated bilaterally. Of the 43 treated breasts, 25 (58 percent) were reconstructed with implants, 17 (40 percent) were reconstructed with a TRAM (transverse rectus abdominis muscle) flap, and one (2 percent) was reconstructed with a TRAM and an implant.

**Results:** There were four complications (8.5 percent) in 47 treated breasts: one breast with cellulitis that resolved with antibiotics and three breasts with small, superficial lumps—two of which were biopsied and found to be liponecrotic cysts. Patient follow-up averaged 49 weeks, ranging from 3 weeks to 6 years. There was a substantial

contour improvement in ten breasts (21 percent), minimal to moderate improvement in 30 breasts (64 percent), and no improvement in 7 breasts (15 percent).

**Conclusions:** Although fat injection in and around the reconstructed breast has limitations, such as fat necrosis and need for repeated injections, our experience indicates that overall it is a very safe technique that can improve or correct significant contour deformities that otherwise would require more complicated, riskier procedures to improve. (*Plast. Reconstr. Surg.* 116: 1300, 2005.)

Although fat injection has been used for at least 20 years to correct both congenital and iatrogenic contour deformities of the face, trunk, and extremities,<sup>1-9</sup> its use in the breast has gone largely unreported and is controversial. The only published accounts in the literature describing the use of fat injection in the breast have been for breast augmentation, and these are case reports detailing either a modest improvement or reporting a complication.<sup>10-12</sup>

There is growing evidence regarding safety, techniques, and efficacy of fat injection in other parts of the body such as the hands and face. We were interested in determining the degree of improvement afforded by fat injection in the reconstructed breast as well as any complications that resulted from using this technique, particu-

From the Division of Plastic Surgery, Georgetown University Hospital. Received for publication June 22, 2004; revised January 18, 2005. Presented at the 21st Annual Plastic Surgery Day and Bernard Sarnat Lectureship at Cedars-Sinai Medical Center, in Los Angeles, California, April 24, 2004.

DOI: 10.1097/01.prs.0000181509.67319.cf

larly given the controversy surrounding the procedure. This controversy largely centers on the theoretical complication of lumps caused by fat necrosis and their potential to mimic the diagnosis of cancer recurrence.

Breast reconstruction successfully may be accomplished using either prosthetic or autologous techniques, or some combination of the two. Extensive experience with these techniques has led to progressive refinements that have raised the aesthetic standard for the reconstructed breast. Patients and surgeons alike are no longer satisfied with a simple "mound," be it of prosthetic or autologous origin.

This article describes the experience of the senior author (Spear), who has used fat injection since 1993 to correct contour deformities in breasts reconstructed by either prosthetic or autologous methods. This experience was first presented informally at local meetings and the annual American Society of Plastic Surgeons meeting in San Diego in October of 2003. It was first formally presented by the senior author (Spear) at the 21st Annual Plastic Surgery Day and Bernard Sarnat Lectureship at Cedars-Sinai Medical Center in Los Angeles on April 24, 2004.

#### PATIENTS AND METHODS

A retrospective review identified 37 patients from 1993 to 2003 who underwent fat injection to address contour deformities in their reconstructed breasts and whose medical records could be located. The same surgeon (Spear) operated on all patients, and all autologous fat grafting procedures were performed at the same institution (Georgetown University Hospital) using the same fundamental surgical technique. Each patient was marked preoperatively in the standing position (Fig. 1).

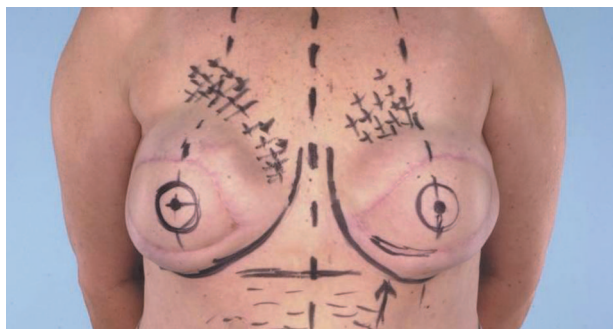


FIG. 1. Example of preoperative markings (performed with patient standing). Areas marked with a + sign indicate where soft tissue augmentation with fat injection will be performed.

Fat was harvested using the Tulip low-pressure syringe lipoaspiration system and then treated with repetitive saline washing until all gross blood products were removed. Fractional injection into depressions primarily around the periphery of the reconstructed breast was performed with multiple passes through separate tunnels.

Data were collected regarding the procedure date(s), type of breast reconstruction, amount of fat injected, time of follow-up, and the occurrence of any complications. Finally, an independent, blinded panel of physician observers judged preoperative and postoperative photographs to determine the degree of contour improvement in one of three categories: substantial, minimal to moderate, or none.

#### RESULTS

In the 37 patients whose complete records were located, a total of 43 breasts underwent fat injection in 47 discrete events. Six patients were treated bilaterally. Three patients had the procedure repeated; one of these patients had a third treatment. Of the 43 treated breasts, 25 (58 percent) were reconstructed with implants, 17 (40 percent) were reconstructed with TRAM flaps, and one (2 percent) was reconstructed with a TRAM and implant. The amount of fat injected per breast during each procedure ranged from 30 cc to 260 cc (average, 116 cc).

There were four complications (8.5 percent) in 47 treatments. One patient with bilateral implant reconstructions who underwent fat injection of 160 cc on each side suffered a cellulitis of the left breast presenting 2 weeks postoperatively that resolved with antibiotics, without implant removal. There were no sequelae from this event although the result was judged to be no improvement. Three patients were found to have small, superficial lumps, each of which were in an area of prior fat injection. Removal of two of these 1-to-2 cm lumps revealed liponecrotic cysts. One of these patients with an implant reconstruction had 260 cc fat injected; her result was judged to be a "substantial" improvement (Fig. 2).

Several other patient results are pictured; the patient pictured in Figure 3 had a TRAM, latissimus-plus-implant reconstruction who underwent three separate procedures involving fat injection around the periphery of the reconstructed left breast. The patient in Figure 4 had a right thoracic hypoplasia treated with an

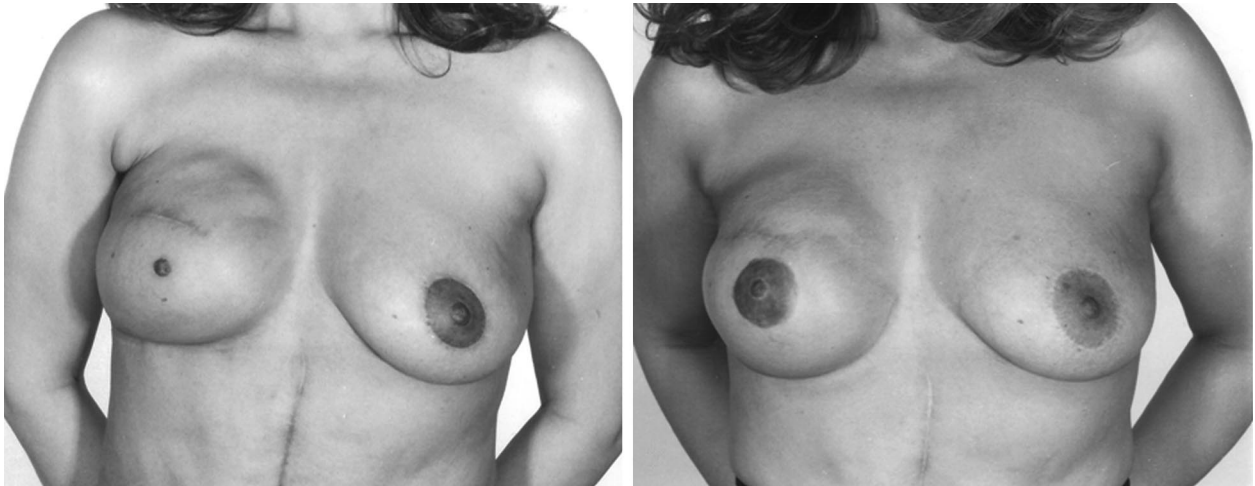


FIG. 2. (Left) Preoperative photograph (after implant reconstruction and nipple reconstruction). (Right) Nearly 2 years after 260 cc fat injection to improve contour in superomedial and superolateral quadrants of the right breast. This patient had a biopsy of a mass that was found to be fat necrosis. Our panel judged this a “substantial” improvement.

implant and then two procedures of fat injection to the right upper pole.

Patient follow-up averaged 15 months, ranging from 3 weeks to 7 years. The majority (35 out of 43 breasts) had follow-up greater than 3 months after their last procedure. After each treatment, our panel judged substantial contour improvements in 10 breasts (21 percent), minimal to moderate improvement in 30 (64 percent) and no improvement in 7 (15 percent). No implant ruptures occurred as a result of fat injection.

#### DISCUSSION

Fat injection has been used for more than 20 years as a relatively low-risk and low-morbidity procedure to correct a variety of soft-tissue defects in the face, trunk, and extremities.<sup>1-9</sup> Its use in the breast has been limited, however, and virtually unreported in the literature.

The reason the reconstructive surgical community resists this type of procedure in the breast is the complication of fat necrosis and the lump that might result. In patients with implant reconstructions (the majority in our series), the risk of infection was a significant factor in the slow accrual of this series out of concern for infecting or otherwise damaging the implant.

These mastectomy patients did not undergo routine post-reconstruction mammography. Despite some reports of the utility of this practice,<sup>12-14</sup> it is still a matter of debate in the literature<sup>15</sup> and, in our current opinion, not warranted. The three patients in our series who *did* return to us with mammograms or ultra-

sounds were the three with palpable masses. Mammograms of two of these patients had the radiographic appearance of fat necrosis. These two patients elected to undergo biopsies of these areas; histopathology confirmed radiographic impression.

Our experience with both implant and TRAM flap breast reconstructions reveals that there are frequently areas of contour irregularity. These are often in the superior portion of the breast, the area of the breast most likely to be visible in low-cut clothing or a bathing suit and therefore the most socially relevant. Other options for soft-tissue augmentation in this have been limited to procedures with significantly more morbidity, such as a muscle-only latissimus dorsi flap or dermal fat grafts.

Regardless of how successful the breast reconstruction is, whether by flap or implant, it is the nearly universal experience of surgeons that many patients will have some contour irregularities. Our 10-year experience in 43 reconstructed breasts indicates that fat injection can improve these areas in the majority of patients, with sometimes-dramatic results. These contour irregularities would otherwise go uncorrected, unless significantly more complicated or risky procedures are performed. At worst, fat injection was complicated by cellulitis or fat necrosis in a small number of patients for whom the procedure did prove beneficial or otherwise harmless. In the few patients who did not benefit at all, the fat simply resorbed, resulting in neither improvement nor complications. We recommend lipoaugmentation of the augmented breast as a safe and effective tool

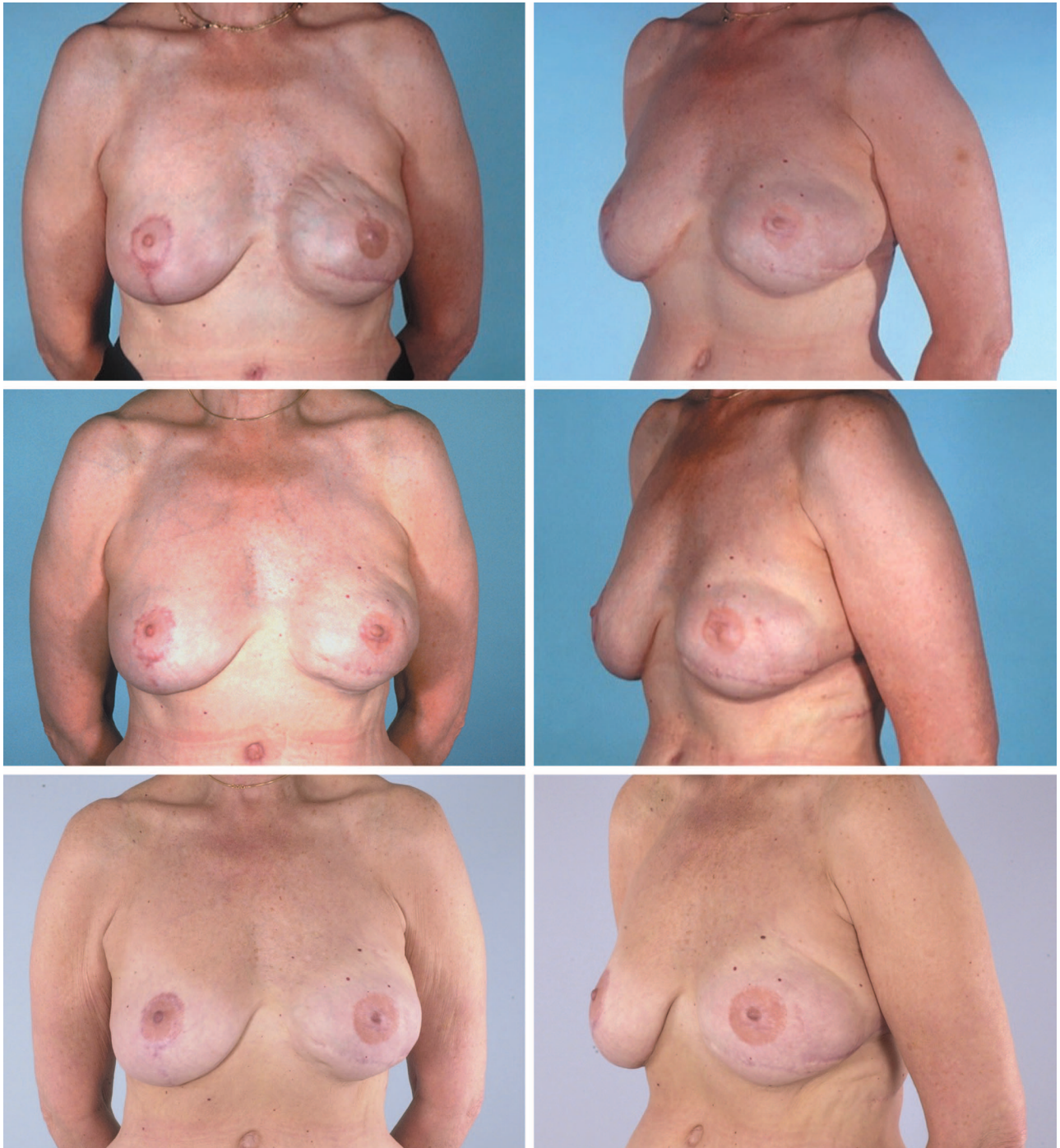


FIG. 3. Patient who underwent three separate procedures, approximately 3 months apart, involving fat injection around the periphery of the reconstructed left breast. Reconstruction was performed with a TRAM plus implant. (*Above*) Before the second episode of fat injection. (*Center*) Results of second episode of fat injection. (*Below*) 3-year follow-up after the third round of fat injection. Our panel judged each round of injection to be a “minimal to moderate” improvement.

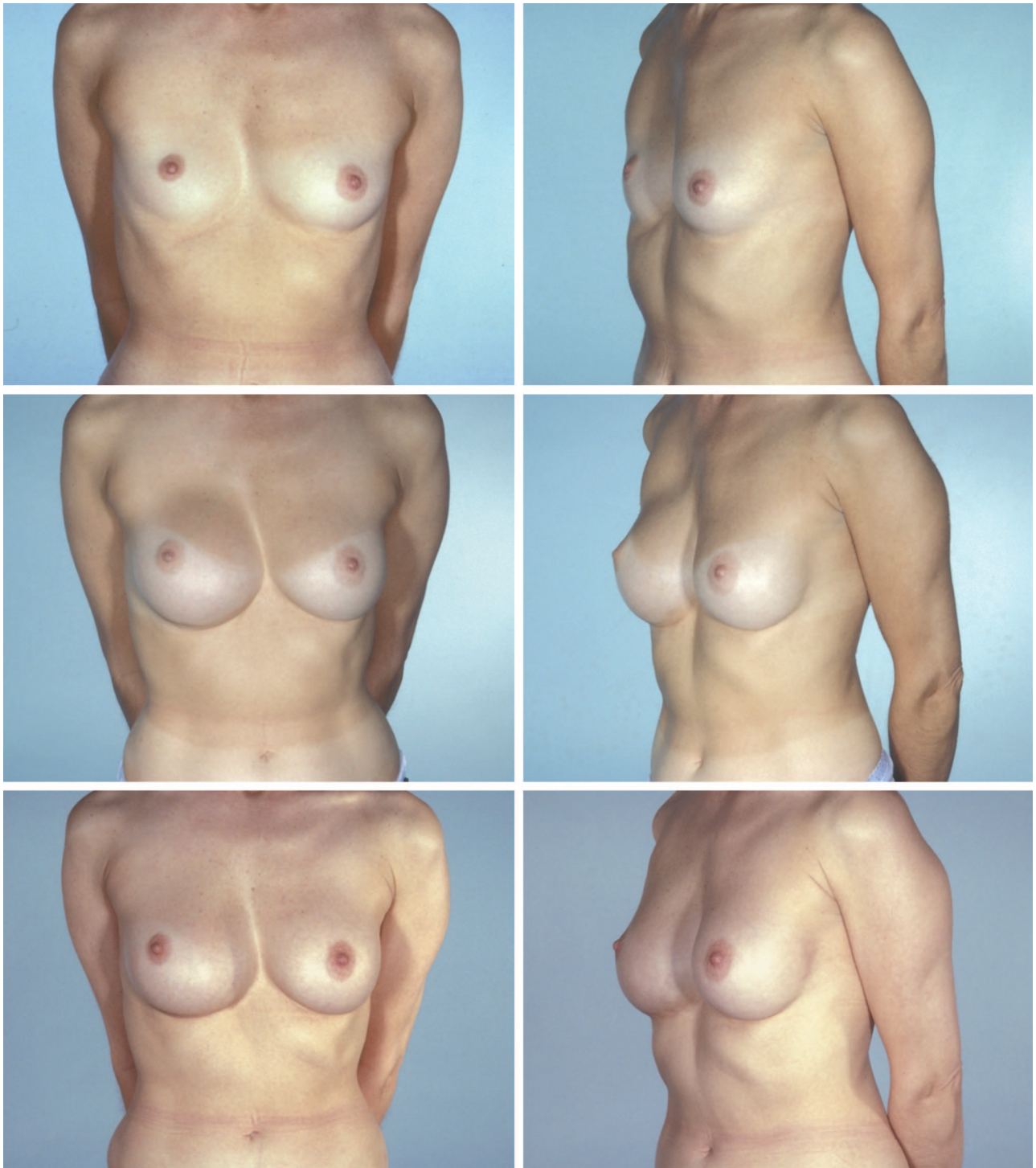

FIG. 4. 39-year-old female with right thoracic hypoplasia. (*Above*) Preoperative photographs. (*Center*) After bilateral submuscular augmentation. (*Below*) Two years after second procedure of fat injection to upper pole of right breast (first 140 cc then 150 cc were injected). This was judged by the panel to be a "significant" improvement.

for improving the cosmetic result of either autologous or implant breast reconstruction.

Scott Lawrence Spear, M.D.  
Georgetown University Hospital  
Division of Plastic Surgery  
3800 Reservoir Road  
First Floor PHC Building  
Washington, DC 20007  
spears@gunet.medstar.net

#### REFERENCES

1. Chajchir, A. Liposuction fat grafts in face wrinkles and hemifacial atrophy. *Aesth. Plast. Surg.* 10: 115, 1986.
2. Chajchir, A., and Benzaquen, I. Fat-grafting injection for soft-tissue augmentation. *Plast. Reconstr. Surg.* 84: 921, 1989.
3. Ellenbogen, R. Free autogenous pearl fat grafts in the face: A preliminary report of a rediscovered technique. *Ann. Plast. Surg.* 16: 179, 1986.
4. Ersek, R. Transplantation of purified autologous fat: A 3-year follow-up is disappointing. *Plast. Reconstr. Surg.* 87: 219, 1991.
5. Ersek, R., Chang, P., and Salisbury, M. Lipo layering of autologous fat: An improved technique with promising results. *Plast. Reconstr. Surg.* 101: 820, 1998.
6. Illouz, Y. The fat cell "graft": A new technique to fill depressions (Letter). *Plast. Reconstr. Surg.* 78: 122, 1986.
7. Nguyen, A., Pasyk, K., Bouvier, T., Hassett, C., and Argenta, L. Comparative study of survival of autologous adipose tissue taken and transplanted by different techniques. *Plast. Reconstr. Surg.* 85: 378, 1990.
8. Niechajev, I., and Sevcuk, O. Long-term results of fat transplantation: Clinical and histologic studies. *Plast. Reconstr. Surg.* 94: 496, 1994.
9. Teimourian, B. Repair of soft-tissue contour deficit by means of semiliquid fat graft (Letter). *Plast. Reconstr. Surg.* 78: 123, 1986.
10. Bircoll, M. Cosmetic breast augmentation utilizing autologous fat and liposuction techniques. *Plast. Reconstr. Surg.* 79: 267, 1987.
11. Castello, J., Barros, J., and Vazquez, R. Giant liponecrotic pseudocyst after breast augmentation by fat injection. *Plast. Reconstr. Surg.* 103: 291, 1999.
12. Mandrekas, A., Zambacos, G., and Kittas, C. Cyst formation after fat injection. *Plast. Reconstr. Surg.* 102: 1708, 1998.
13. Leibman, A. J., Styblo, T. M., and Bostwick, J., III. Mammography of the postreconstruction breast. *Plast. Reconstr. Surg.* 99: 698, 1997.
14. Dowden, R. V. Mammography after implant breast reconstruction. *Plast. Reconstr. Surg.* 96: 119, 1995.
15. Langstein, H. N., Cheng, M., Singletary, S. E., et al. Breast cancer recurrence after immediate reconstruction: Patterns and significance. *Plast. Reconstr. Surg.* 111: 712, 2003.